

Haemogram Parameter of 17 Dogs That Have Been Infected by *Ehrlichia canis* in My Vets Animal Clinic Kemang in 2017

Tri Ayu Kristianty^{1*}, Ni Nengah Yogiswari Resyana¹

¹Veterinary Practioner in My Vets Animal Clinic Kemang, Jakarta, Indonesia

*Corresponding author

Keywords: *Ehrlichia canis*, ehrlichiosis, leucopenia, anemia, thrombocytopenia.

INTRODUCTION

Ehrlichiosis is a canine vector-borne disease transmitted by ticks. It is caused by a gram-negative obligate intracellular bacteria of the genus *Ehrlichia*. *Ehrlichia* has three different species that can cause canine ehrlichiosis: *E. canis*, *E. chaffeensis*, and *E. ewingii*.

Ehrlichia canis causes canine monocytic ehrlichiosis (CME) that is also known as tropical canine pancytopenia, canine rickettsiosis or canine hemorrhagic fever. Primary vectors of *E. canis* are *Rhipicephalus sanguineus* and *Dermacentor variabilis*. CME is characterized by three stages, acute, subclinical, and chronic that can be difficult to definitively distinguish in practice.

E. canis form microcolonies within a membrane-lined intracellular vacuole that is also called morula, primarily in monocytes and macrophages of mammalian hosts. The pathogen replicates only in cytoplasm of monocytic cells and the formation of morulae is defining characteristic that can be used for diagnosis.

A case ehrlichiosis in canine can be diagnosed based on clinical signs, blood smear examination, cell culture, serology test, or molecular detection by polymerase chain reaction (PCR).

CASE REPORT

A total of 17 dogs (8 females and 9 males) were presented to My Vets Animal Clinic Kemang, Jakarta, with history of lethargy, inappetance, and tick infestation. The dogs consist of 15 purebreds and 2 mixed breeds with an average age 1-15 years. On physical examination all of them have been shown a mild pale mucous membrane and first to second degree of dehydration.

Blood samples were collected in EDTA vial for complete blood count (CBC) examination and serology test for blood parasites by using IDEXX SNAP 4Dx Plus Test. All of the dogs shown positive antibody of *Ehrlichia canis*.

The CBCs shown 41.2% dogs had leucopenia (7/17), 29.4% had leukocytosis (5/17), and 29.4% had normal leucogram (5/17). The four leucocyte cells that change parameters were

lymphocytes, monocytes, eosinophils, and neutrophils. Lymphopenia has been shown in 41.2% dogs (7/17), monocytopenia in 17.7% dogs (3/17), eosinophilia in 23.5% (4/17), neutrophenia 23.5% dogs (4/17), and neutrophilia in 17.7% dogs (3/17). Almost all of the dogs had anemia (decreased red blood cells, haemoglobin, and haematocrit). The percentage was 88.2% (15/17) and about 82.3% dogs (14/17) had thrombocytopenia.

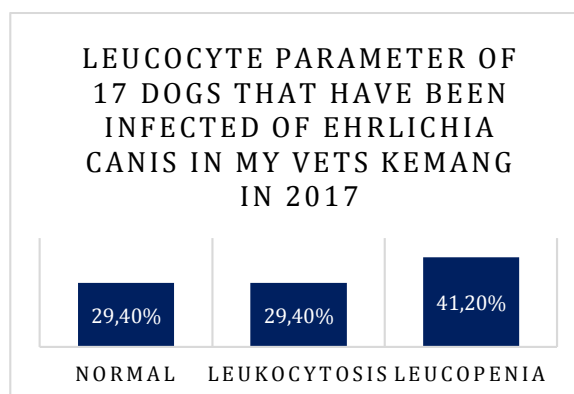


Chart 1. Leucocyte parameter of 17 dogs that have ben infected of *Ehrlichia canis* in My Vets Kemang in 2017

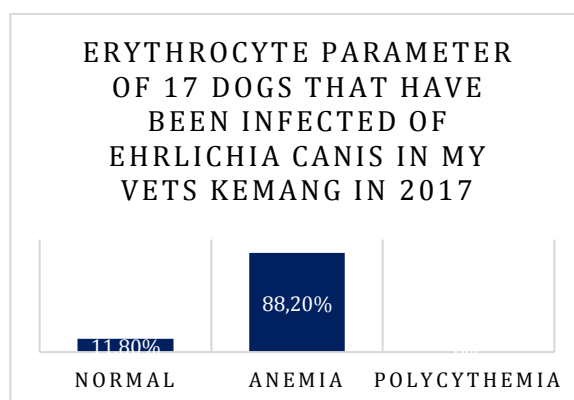


Chart 2. Erythrocyte parameter of 17 dogs that have ben infected of *Ehrlichia canis* in My Vets Kemang in 2017

THROMBOCYTE PARAMETER OF 17 DOGS THAT HAVE BEEN INFECTED OF EHRLICHIA CANIS IN MY VETS KEMANG IN 2017

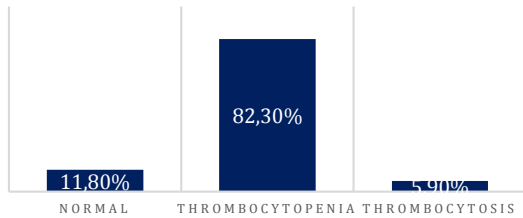


Chart 3. Thrombocyte parameter of 17 dogs that have been infected of Ehrlichia canis in My Vets Kemang in 2017

DISCUSSION

A complete blood count is an important tool for the diagnosis of canine monocytic ehrlichiosis (CME). Variable degrees of leucopenia and thrombocytopenia may be present. Thrombocytopenia is most common hematological finding in Ehrlichiosis (Waner *et al.* 2000). Thrombocytopenia usually becomes severe in the chronic phase accompanied by marked anemia and leucopenia. Pancytopenia due to bone marrow hypoplasia is characteristic of the chronic severe form (Harrus *et al.* 1997). Variations in haematological profiles in Ehrlichia canis infected dogs may be related to differences in the virulence of Ehrlichia canis strains, antigen heterogeneity of this bacterial agent and the clinical form of the disease.

Leucopenia was observed in 41.20 % (7/17) of the cases. Ehrlichia spreads through blood and lymphatic vessels. Lymph and body fluid, carries cells that help fight infection. Ehrlichia invades certain cells (monocytes and macrophages) that play an essential role in the body's immune system by engulfing and digesting microorganisms. Decreased in monocyte has been postulated that some monocytes infected with Ehrlichia canis would adhere to the vascular endothelium, leading to reduction in their peripheral blood numeration (Ettinger 2000)

The thrombocytopenia in CME is attributed to different mechanisms in the different stages of the disease. Mechanisms though to be involved in the pathogenesis of thrombocytopenia in the acute phase of the disease include increased platelet consumption due to inflammatory changes in blood vessel endothelium, increased splenic sequestration of platelet, and immunologic destruction or injury resulting in a significantly decreased platelets life span (Harrus *et al.* 1999). Thrombocytopenia shown in 82.30% (14/17) in this cases.

Anaemia is also a common clinical pathology abnormality in canine ehrlichiosis. Anaemia in dogs with *E. canis* infections results from haemorrhage and/or bone marrow suppression. Although erythrophagocytosis is prominent in the lymph nodes, this is not a feature in the other organs, and the erythrophagocytosis is thought to result from haemorrhage rather than sensitization of red blood cells (Kelly 2000). In this cases, anemia was shown in 88.20% dogs. (15/17).

CONCLUSION

Ehrlichia canis is a tick borne disease transmitted by *Rhipicephalus sanguineus* or *Dermacentor variabilis*. *Ehrlichia canis* can cause leucopenia, anemia and thrombocytopenia to the dogs.

REFERENCE

- [1] Ettinger J, Feldman C. 2000. Diseases of the dog and cat. In: Textbook of Veterinary Internal Medicine. 5th edition, W.B.Saunders Co., Philadelphia, , pp.: 402-406.
- [2] Harrus S, Kass PH, Klement E, Waner T. 1997. Canine monocytic ehrlichiosis: a retrospective study of 100 cases, and an epidemiological investigation on prognostic indicators for the disease. *Vet. Rec.*141, 360-363.
- [3] Harrus S, Waner T, Bark H, Jongejan F, Cornelissen AWCA. 1999. Minireview: Recent Advances in Determining the Pathogenesis of Canine Monocytic Ehrlichiosis. *J. Clin. Microb.* Vol.37 (9): 2745-2749.
- [4] Kelly PJ. 2000. Review article: Canine ehrlichiosis: an update. *Jl. S. Afr. Vet. Ass.* 71(2): 77-86.
- [5] Waner T, Leykin I, Shinitzky M, Sharabani E, Bunch H, Keysary A, Bark H, Harrus S. 2000. Detection of platelet-bound antibodies in beagle dogs after artificial infection with *Ehrlichia canis*. *Vet. Immunol. Immunopathol.* 77: 145-150.