

Molecular Detection of Hemagglutinin Gene Fragment of Avian Influenza Virus H9 Subtype Obtained from Poultry Commercial Farm with Prominent Symptom of Decreased Egg Production

Niken Respati Maharani^{1,2}, Heru Susetya³, Michael Haryadi Wibowo^{4*}

¹Master Program, Faculty of Veterinary Medicine, University of Gadjah Mada, Yogyakarta, Indonesia

²Disease Investigation Center Subang, Ministry of Agriculture of The Republic of Indonesia, Subang, Indonesia

³Department of Veterinary Public Health, Faculty of Veterinary Medicine, Gadjah Mada University, Yogyakarta, Indonesia

⁴Department of Microbiology, Faculty of Veterinary Medicine, Gadjah Mada University, Yogyakarta, Indonesia

ARTICLE INFO

Article history:

Received November 22, 2021

Received in revised form February 17, 2022

Accepted March 29, 2022

KEYWORDS:

amplification,
avian influenza,
characteristic lesion,
cladus,
subtype

ABSTRACT

Avian influenza virus H9N2 subtype is considered a low pathogenic strain that has been reported in Indonesia since late 2016. The outbreak has caused economic losses for farmers due to the sharp drop in egg production. The evidence of the existence of AIV H9N2 has been published, but very limited information on the prominent symptom and macroscopic lesion. This research was a retrospective study of suspected avian influenza H9 subtype, obtained from layer commercial farm with recorded characteristic symptoms. Specific trachea samples were collected and further processed to be isolated, propagated using embryonated chicken egg, and then extracted the RNA for molecular detection using real-time reverse transcriptase-polymerase chain reaction (RT-qPCR). A positive result was further detected in its H-9 gene with RT-PCR technique and sequencing methods. One of five samples showed positive for RT-qPCR with CT value 30.19. Sequence analysis confirmed that the sample with characteristic macroscopic lesion could be detected in the presence of the AIV H9 subtype. Phylogenetic tree analyses revealed that this virus belongs to the China-Vietnam- Indonesia (CVI) lineage.

1. Introduction

Avian influenza is caused by infection with Influenza virus type A, which belongs to the family Orthomyxoviridae, genus Influenzavirus. The AI virus has a wide range of hosts, particularly in all bird species, including domesticated poultry. In addition, the particular virion is pleomorphic and composed of single-stranded RNA with negative sense polarity. The viral RNA encodes 10 proteins found on the surface of the virion and capsid. Surface glycoproteins consist of hemagglutinin (HA) and neuraminidase (NA), and matrix-2 (M2). Capsid proteins include nucleoprotein (NP), polymerase basic (PB-1 and PB-2), polymerase acidic (PA), matrix-1 (M1), and non-structural protein, which consists of NS-1 and NS-2. The antigenic character of the M and NP proteins determines the type of influenza A virus, while the subtype is based on the antigenic character of HA and NA proteins (Cox and Kawaoka 1998). So

far, influenza virus A has been characterized by 18 HA and 11 NA subtypes (Tong *et al.* 2013). Most avian influenza subtypes are reported as LPAI but already known that traditionally HPAI has been either H5 or H7 subtype.

Among the many subtypes, the H9N2 is thought to be most prevalent in the domestic poultry industry (Lee and Song 2013; Peacock *et al.* 2019). An outbreak of the H9N2 virus has been an enzootic disease in Asia, the Middle East, West Africa, and North Africa since the early 1990s. Based on the capability to cause mortality in poultry, the AI virus is classified into highly pathogenic avian influenza (HPAI) and low pathogenic avian influenza (LPAI) (OIE 2018). At a molecular level, pathogenicity is associated with the presence of multiple basic amino acids at the cleavage site of HA protein. The cleavage site region of the HPAI virus differs from those of LPAI by possessing multiple basic amino acids of the carboxy-terminus of hemagglutinin, especially arginine and lysine (Horimoto and Kawaoka 2001). According to the molecular level and clinical characteristics of the H9N2 virus is classified as the LPAI virus (OIE 2018).

* Corresponding Author

E-mail Address: mhwbw@ugm.ac.id

The clinical sign of the AI H9N2 virus infection does not show a specific symptom. Most H9N2 virus infections cause a respiratory disorder similar to that caused by other avian respiratory pathogens. Usually, that symptom is accompanied by depression in the bird, decreased feed consumption, diarrhea, and decreased eggshell quality and production in the layer hen (Capua and Marangon 2000; Aamir *et al.* 2007; Lee *et al.* 2015; El-Houadfi *et al.* 2016). According to El-Houadfi *et al.* (2016), laying hens with a sharp decrease in egg production, reaching 80%, showed incomplete disease recovery. It was also reported that up to 10 weeks after infection, egg production was still around 20-25% lower than normal levels. However, some cases of H9N2 infection have been reported to cause high morbidity and mortality in the presence of co-infection (Nili and Azasi 2002).

An outbreak of H9N2 virus infection was reported in Indonesia by the end of 2016 that occurred in laying commercial farms in Sidrap, South Sulawesi. The recognized symptoms were respiratory problems, such as coughing, sneezing, and gasping, accompanied by diarrhea and a drop in egg production that reached up to 78%. However, the mortality rate was low (5%). Molecular detection was confirmed that the cases were caused by the H9N2 virus (Muflihanah *et al.* 2017). The disease continues to spread to other provinces, as Jonas *et al.* (2018) reported. According to that report, the decrease in egg production varies between 5 to 50% and happens in both the commercial layer and breeder in Indonesia. It was evidence that AIV H9N2 subtype infection is become a significant threat to the poultry industry due to its economic importance.

To date, the decrease in egg production in laying hens is still reported in the field, which is thought to be due to H9N2 virus infection. That problem confuses the farmer in farm conditions since the other agent could have a similar symptom. This study aimed to report the clinical and gross pathological findings and confirm the cause of the drop in egg production in commercial hens with a molecular approach.

2. Materials and Methods

2.1. Sample Isolation in Embryonic Chicken Egg

The samples were collected from commercial layer farm experiences with decreased egg production. The trachea was chosen as an important organ for detecting the LPAI virus H9N2 subtype. The sample list is as follows (Table 1).

Table 1. List of samples used in this study

Sample code	Description
D1: Pool of tracheal organs RHB-3	Decreased production up to 40%, eggshell quality is decreased
D5: RHB-2 tracheal organ pool	Decreased production up to 40%, eggshell quality is decreased
B8: Tracheal organ pool Layer-bara	Decreased production reached 15%, the eggshell quality is decreased, torticollis
B9: Grower's tracheal organ Pool-bara	Symptoms of respiratory distress, torticollis
H9: Pool of tracheal organs RHB-1	Decreased production up to 40%, eggshell quality is decreased

Propagation was carried out by inoculating the sample into the 11-days Embryonated Chicken Eggs (ECE) with a negative antibody to AIV. The propagation is carried out in the biosafety cabinet facility-level 2+. The inoculated eggs were incubated at 37°C and observed for 5 consecutive days. The dead ECE was chilled for 24 hours before the allantoic liquid was harvested. Allantoic fluid harvested from all eggs was then tested for rapid haemagglutination (HA) test. Positive HA will be followed by a haemagglutination inhibition test using specific antisera (WHO 2002).

2.2. Avian Influenza Virus H9 Subtype Identification with RT-qPCR

The RNA extraction process was used the Viral Nucleic Acid Extraction Kit II from Geneaid (Cat No: VR 300; Lot No. FG07703-G). The obtained RNA extract was then amplified through the RT-qPCR machine of the Stratagene Mx3005p (Agilent Technologies) using primers and probes sequences designed by the Laboratory of Australian Animal Health Laboratory, Geelong, Australia (Table 2). Bioline SensiFAST Probe Lo-ROX One-Step Kit (Cat. No. BIO-78005; Lot. No. SF623-B081610) was used to detect AI virus subtype H9.

The reagent was mixed with the RNA template to produce a total volume of 25 µl. Cycling conditions for the reaction were as follow: a reverse transcription was set up at 45°C for 10 minutes and polymerase activation at 95°C for 10 minutes. The amplification of the H9 gene was carried out for 45 cycles consisting of a denaturation phase was 95°C for 15 seconds, and an annealing/extension was 60°C for 45 seconds. Analyses of the test results were obtained from the interpretation of the Ct value through fluorescence data displayed on the instrument monitor screen.

Table 2. Oligonucleotide Primer and Probe for H9 RT-qPCR detection (AAHL, Geelong Australia)

Name	Sequence (5'-3')
H9	
PrimaryH9F	ATG GGG TTT GCT GCC
PrimaryH9R	TTA TAT ACA AAT GTT GCA CTC TG
ProbeH9	/56-FAM/TTC TGG GCC ATG TCC AAT GG/36-TAMSp/

The samples tested showed positive results if the Ct value was <40, indeterminate if the Ct value was 40-45, and negative if the Ct value was >45 and used a threshold value of 0.1 (Dirjen PKH, Kementerian Pertanian 2018).

2.3. Hemagglutinin gene (H9) amplification with RT-PCR

Amplification on the H9 gene fragment was conducted using a primer to the prior work, which had a forward primer: 5'-cty cac aca gar caca at gg-3'; and reverse primer: 5'-gty aca ctt ctt gtt gtr tc-3'- and PCR product length was 500 bp. The RT-PCR reaction condition was as follows; First, RT was conducted at 55°C for 30 minutes, followed by pre-denaturation at 95°C for a minute. Next, PCR was conducted for 35 cycles of denaturation at 95°C for 20 seconds, annealing at 55°C for 45 seconds, and an extension at 72°C followed for 1 minute. Then a final extension was performed at 72°C for 4 minutes. PCR product was analyzed with electrophoresis in 1.5% Agarose gel. The positive result was sent to First BASE, (Apical Scientific, Selangor Malaysia) for being sequenced.

Sequence products were analyzed using the bioinformatics tool of MEGA X, including nucleotide translation, amino acid prediction, and multiple alignments with selected H9 AIV gene from representative of Y439, G1, BJ94, Y280, and CVI lineage obtained from the gene bank. Trimming was done to fix the electropherogram files to set up the quality and intact sequence. The good quality of the electropherogram is then translated into nucleotide sequences. To determine the mature H9 is used the online program HA Subtype Numbering Conversion from the Influenza Research Database (Burke and Smith 2014). The alignment of nucleotides data was performed with clustal W by comparing with other H9N2 Indonesia isolates from GeneBank. A

phylogenetic tree is generated through the neighbor-joining method with bootstrap values of 1,000 replicates (Kimura 1980).

3. Results

3.1. Clinical Characteristic and Pathological Finding

Sample codes RHB-1, 2, and 3 were obtained from a 3-shed farm in Central Java. Each code of sample consisted of 3 birds with prominent clinical signs, a drop in production up to 40%, and decreased quality of eggshell, including soft eggshell, cracked egg, and decolorized egg (Figure 1A). Other symptoms of the bird showed a respiratory disorder; drop in feed intake and watery diarrhea. One sample group was layer chicken with the same clinical sign above, but with a 15% drop in egg production, accompanied by torticollis obtained from East Java. One sample was collected from a pullet farm in East Java with prominent symptoms was respiratory disorder. During necropsy, tracheitis exudative (Figure 1C) was consistent for all samples, peritonitis, and oophoritis with a specific feature called 'broccoli' (Figure 1B) observed in 3 groups of samples of layer chicken code RHB1, 2, and 3. A white spot with yellowish exudates was observed in the oviduct (Figure 1D).

3.2. Virus Isolation and RT-qPCR Virus Detection

The results of isolation and propagation on samples of RHB-2 and RHB 3, showed negative results after two passages in the embryonic chicken eggs. Confirmation of H9 virus detection by RT-qPCR exhibited negative results. However, the RHB-1 tracheal organ pool indicated a positive RT-qPCR result, so the sample was further propagated into the 3rd passage. The rapid HA test of the allantoic fluid harvested from the 3rd passage did not show any erythrocyte agglutination that could be concluded no virus growth.

Detection by RT-qPCR of the H9 gene fragment on 5 samples examined in this study showed 4 negative samples. One sample with code H9: RHB-1 tracheal organ pool indicated positive results with a CT value of 30.19. The RT-qPCR data can be found in Table 3.

According to the RT-qPCR technique, a positive result is indicated by the appearance of an increase

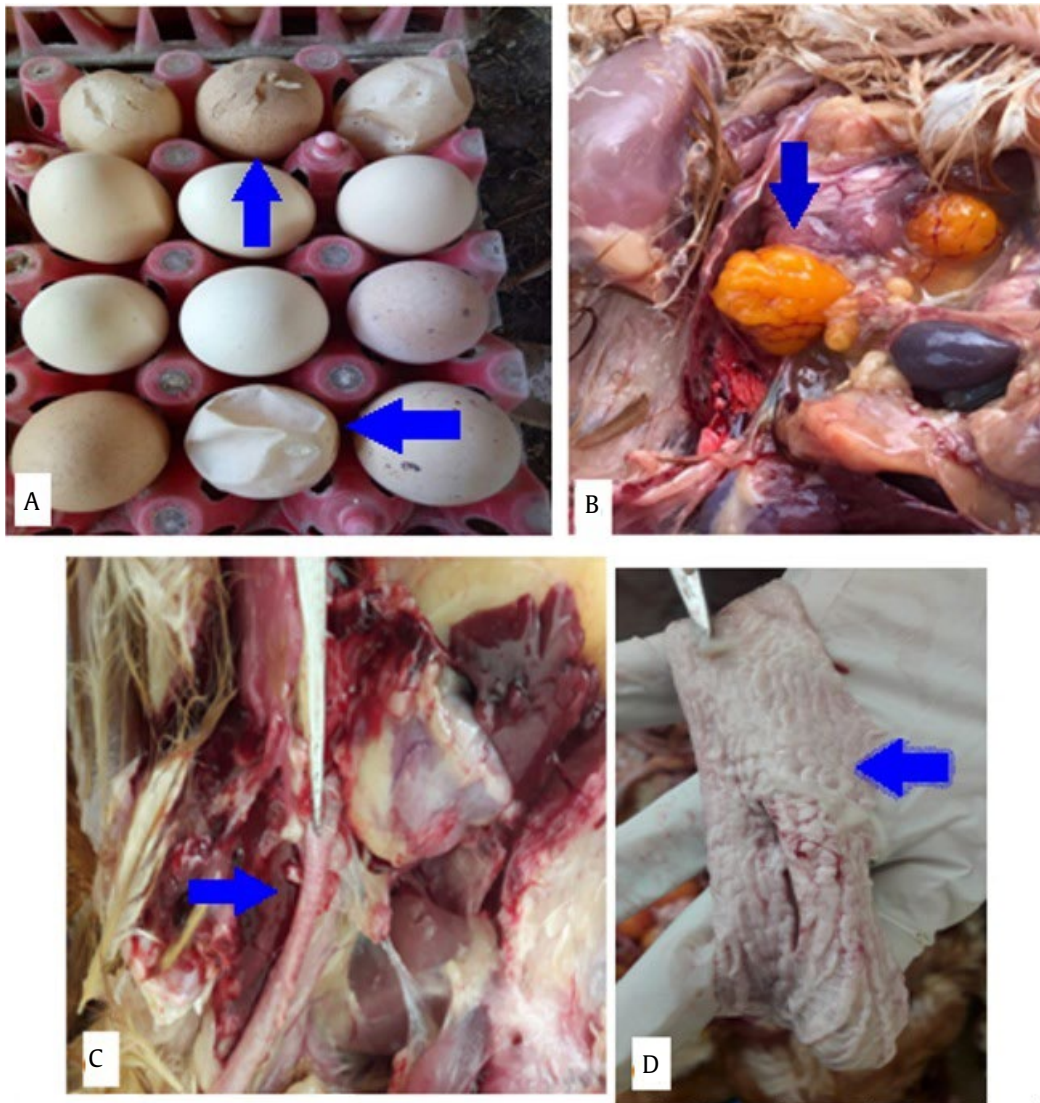

Figure 1. (A) Decreased quality of eggshell (soft eggshell and cracked egg), (B) oophoritis with a specific feature called 'broccoli', and peritonitis (C) tracheitis exudative, (D) white spot exudate in the oviduct

Table 3. The result of RT-qPCR detection of H9 gene fragment

Sample code	CT value and description
D1: Pool of tracheal organs RHB-3	45.00: negative
D5: RHB-2 tracheal organ pool	39.00: negative
B8: Tracheal organ pool Layer-bara	45.00: negative
B9: Grower's tracheal organ Pool-bara	45.00: negative
H9: Pool of tracheal organs RHB-1	30.19: positive

in the fluorescence signal, which is greater than the background fluorescence. The interpretation of a positive result when the CT is <40, and the amplification curve has to be similar to positive control. The parameter sample 5-H9 showed CT-value 30.19 with a curve similar to that control so that it could be concluded as a positive result (Figure 2). Sample 2 (D5) exhibited a CT value of 39.00, but the amplification curve was not similar to the positive control. Therefore, sample 2 (D5) was categorized as a negative result. The result is considered negative when the CT value is greater than 45 and without any

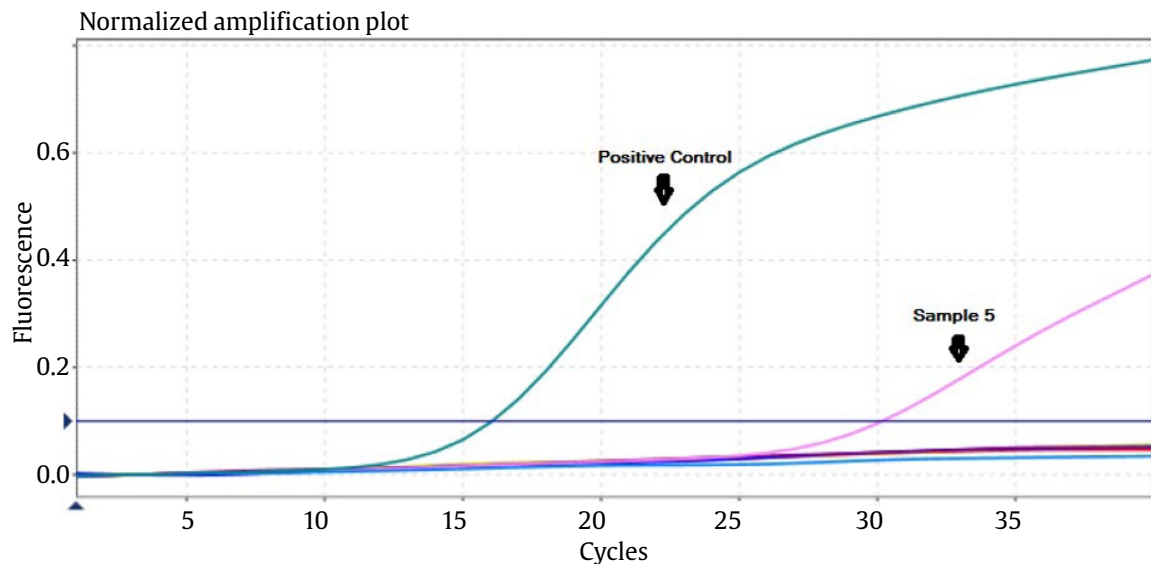


Figure 2. Curve of AI H9 RT-qPCR test results. Positive control showed an increase in the fluorescence signal with Ct value 16.06. Sample of tracheal organs RHB1(sample 5) showed similar Ct value 30.19

amplification curves characteristic of the positive control.

3.3. RT-PCR, DNA Sequence, and Genetic Analysis

Among 2 of 5 results of RT-qPCR were chosen to be amplified using conventional RT-PCR. These are RHB-2 which showed a Ct value of 39.00, and RHB-1, which exhibited a Ct value of 30.19. One of the two samples, RHB-1 that is (A/layer/Rhb-1/MHW/2017) considered positive. The amplification result exhibited a clear, thick, and without any extra band. Meanwhile, amplification of RHB-2 resulted in a very smear DNA band that concluded as negative. The electrophoresis result can be found in Figure 3.

The sequence result was further analyzed to determine the precision of the targeted gene, by comparing the H9 Indonesian sequences gene obtained from the published report. The multiple alignments performed with clustal W were presented in Figure 4.

Based on the amino acids alignment of the H9 gene fragment in this study is matched and precise among the H9 viruses. This data confirmed that the H9 virus obtained in this study is fixed as the H9 virus. Further study of amino acids analyzed of H9 fragment showed the same motif with the Indonesia H9N2 virus that has been previously reported. The antigenic site of the HA gene exhibited the same motif, e.g., at positions 125 S, 135 D, 147 K, 152 P, and 183N. The receptor binding site of A/Layer/Rhb-1/MHW/2017, showed an amino acid composition: 92

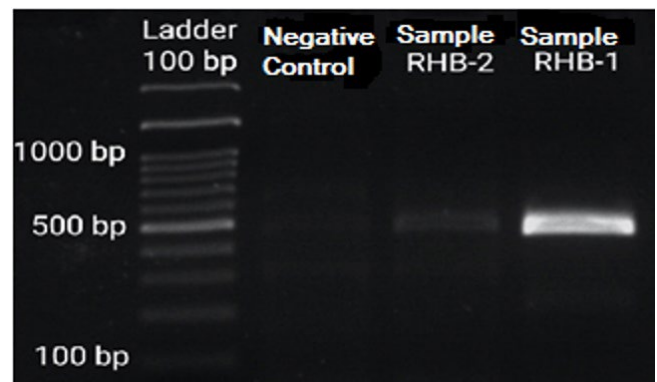


Figure 3. Electrophoresis result that showed a positive result of H9 amplification; 1. DNA ladder, 2. Negative control, 3. Sample RHB-2, 4. Sample RHB-1

P, 143 W, 145 T, 173 N, 180 V, 184 L, and 185 Y. The motif is the same with A/chicken/North Sumatra/VSN873/2017, but different from 4 others isolates. The HA gene fragment sequence for the isolate (A/layer/Rhb-1/MHW/2017) in this study was available at Genbank with the accession number OL589519.

3.4. Phylogenetic Trees Analysis

Based on phylogenetic tree analyses, it was shown that all analyzed viruses were created to be 5 lineages, which were Y439, G1, BJ94, Y280, and CVI lineage. The H9 virus in this study is belonged to the CVI lineage, clusters with other Indonesia viruses. The phylogenetic tree of the H9 fragment gene is presented in Figure 5.

A/layer/Rhb-1/MHW/2017	YGNPSCDLL EGREWSYIVE RPSAVNGLCY PGNVENLEEL RSLFSSARSY QRILIFPDTI WNVSYSGTSK ACSDSFYRSM	[80]
A/Environment/Jakarta/AIV_H9_HA008/2019L.....V.....	[80]
A/duck/Indonesia/04161291-OP/2016	[80]
A/chicken/NorthSumatra/VSN873/2017E.....	[80]
A/Layer/Indonesia/CentralJava-01/2017E.....	[80]
A/chicken/Central_Sulawesi/M92_06/2016V.....	[80]
A/layer/Rhb-1/MHW/2017	RWLTQKDNAY PIQDAQYTNN QEKNILFMWG INHPPTDVIQ TNLVTRDIT T	[131]
A/Environment/Jakarta/AIV_H9_HA008/2019A.....	[131]
A/duck/Indonesia/04161291-OP/2016A.....	[131]
A/chicken/NorthSumatra/VSN873/2017	[131]
A/Layer/Indonesia/CentralJava-01/2017T.....	[131]
A/chicken/Central_Sulawesi/M92_06/2016N.....T.....D.....	[131]

Figure 4. Sequence alignment of 131 amino acid length HA amino acids (at positions 62-192). Alignment of A/layer/Rhb-1/MHW/2017 with Indonesian isolates from CVI lineage. There are similarities between the amino acid motifs of the research sample and isolates from Indonesia

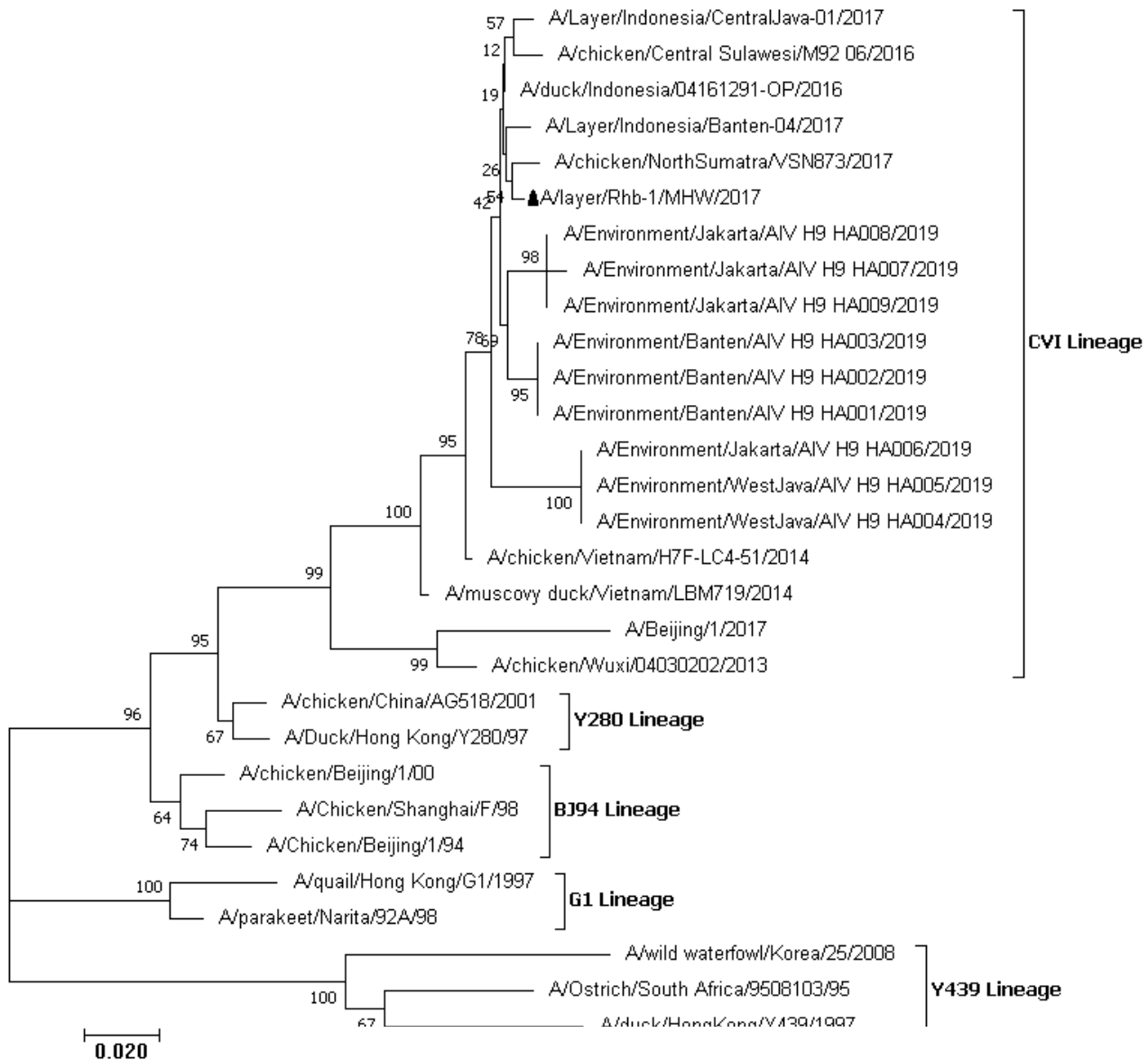


Figure 5. The phylogenetic tree is generated using Mega-X, according to H9 gene fragment at nucleotide position from 184 to 576, with a bootstrap value of 1000X, ▲ H9 virus isolate in this study

4. Discussion

Clinical presentation in the layer commercial farm with decline production sharply in this study is relevant to published data. Lai *et al.* (2021) reported that field cases of LPAI H9N2 strain in layer farms in South Korea showed clinical signs of a respiratory disorder, such as sneezing and gasping, accompanied by egg reduction of over 20%. Several reports confirmed that the AI H9N2 infection did not show apparent clinical symptoms but reduced egg production by 30% (Aamir *et al.* 2007) and up to 80% (El-Houadfi *et al.* 2016). Other field reports of the drop in production in layer farms caused by H9N2 infection in Indonesia reached 70% (Muflihanah *et al.* 2017). However, according to Jonas *et al.* (2018), the decline of egg production in layer farms in Indonesia was only 10 to 50%. According to Bonfante *et al.* (2018), the decreased egg production is suggested due to the acute and sub-acute inflammation in the organ, in particular in the level of infundibulum, which results in impairment of the oviposition of infected hen. Co-infection with *E. coli* and H9N2 virus caused a more serious synergistic pathogenic effect and prominent lesion (Jaleel *et al.* 2017). Decreased egg production and reduced egg quality should be aware of closely related pathogens, such as Infectious Bronchitis (IB) virus, especially variant IB that has been reported in Indonesia (Wibowo *et al.* 2019; Setiawaty *et al.* 2019), or Newcastle Disease virus (Shamuganathan *et al.* 2017; Triosanti *et al.* 2018) or Egg Drop Syndrome infection (Kencana *et al.* 2017).

Pathology macroscopic findings in our study showed various lesions, such as severe tracheitis with tracheal plug, peritonitis, oophoritis with a specific feature of "broccoli," and a white-yellowish spot in the oviduct. This finding is similar to the report of H9N2 infection in layer farms that exhibited tracheitis with caseous plug (Javeen *et al.* 2019; Lai *et al.* 2021). A white to yellowish exudate found in the oviduct and oophoritis with broccoli feature was considered specific lesions that have never been reported in any case the drop of egg production in poultry farms. This finding is supported by experimental infection of the G-1 lineage H9N2 virus in laying hens that resulted in gross pathology of the oviduct with fibrinous clot observed on day 4 post-infection. Another clinical sign of deformed and soft-shelled eggs was found at 4 to 5 days post-infection (Bonfante *et al.* 2018). According to Qi *et al.* (2016), the presence of AIV H9N2 antigen in both the lining and glandular epithelium of the oviduct tissue causes the impairment of the expression of genes related to eggshell quality in the uterus of an infected hen. Meanwhile, peritonitis due to abundant yolk material filling in the abdomen and

the serosa appearing thickened, characterized by yellowish pigmentation, is relevant to Bonfante *et al.* (2018) report. In the field condition, egg peritonitis is often considered the multifactorial causative agent.

To confirm the presence of H9 infection, we conducted molecular detection of H9 gene fragment amplification by using both RT-qPCR and RT-PCR conventional. One of five samples (A/layer/Rhb-1/MHW/2017) was considered positive with a curve of CT value was 30.19. Amplification using RT-PCR exhibited a clear, thick, and without any extra band. Meanwhile, negative amplification of other samples could be due to various factors, including that the RNA viruses were damaged or viral RNA degradation had occurred. The other negative samples for H9 virus detection using RT-qPCR could be true negative because the causative agent was not the H9 LPAI virus. The data is supported by the observed clinical sign, torticollis, related to the Newcastle Disease virus (Alexander 2003).

Based on the molecular analysis, the antigenic site at positions 125 S, 135 D, 147 K, 152 P, and 183N showed the same motif as Indonesia H9 LPAI viruses that had been previously reported in Yogyakarta and Central Java (Lestari *et al.* 2019), in Sulawesi (Muflihanah *et al.* 2017), Banten and North Sumatra (Jonas *et al.* 2018; Nugroho *et al.* 2021). The other important residues are the receptor binding site of A/Layer/Rhb-1/MHW/2017, which showed an amino acid composition: 92 P, 143 W, 145 T, 173 N, 180 V, 184 L, and 185 Y. The motif is the same with A/chicken/North Sumatra/VSN873/2017, but different from 4 others isolates. Further analysis indicated that A/layer/Rhb-1/MHW/2017 has a Valine (V) at position 180 on the receptor binding site. The residue is suggested to be correlated with the level of binding affinity of sialyl- α 2,6-galactose, as known as a human cell receptor (Teng *et al.* 2016). The 180-A motif is the same with A/chicken/North Sumatra/VSN873/2017 LPAI virus. Further data exhibited that other Indonesian isolates, such as A/environment/Jakarta/AIV H9 HA008/2019 and A/duck/Indonesia/04161291-OP/2016, showed residue of 180-A. Meanwhile, A/chicken/Central Sulawesi/M9206/2016 and A/layer/Indonesia/CentralJava-01/2017 have 180-T. According to Moosakhani *et al.* (2010), the level of binding affinity is associated with the presence of amino acid residue at position 180, in which 180-A (Alanine) is the lowest, 180-T is medium, and the strongest is 180-V (Valine).

A phylogenetic tree study concluded that the HA-9 fragment gene sequence of this isolate belong to China-Vietnam-Indonesia (CVI) lineage. The data was supported by Indonesian reports by Jonas *et al.* (2018), and Maharani *et al.* (2021) that different

from the Y280 lineage. In contrast with our data, another report of Indonesian H9 LPAI isolated from commercial poultry chicken in Jawa Island has concluded to belong to Y280, but with additional information that those viruses are a genetic link with viruses from China and Vietnam (Nugroho *et al.* 2021).

This research proves that the decreased production of laying hens with typical pathological symptoms as described in this study could be detected and confirmed as an AI virus of the H9 subtype. Based on genetic analysis and construction of the phylogenetic tree, the virus isolates belong to the China-Vietnam-Indonesia (CVI) lineage.

Acknowledgments

Authors gratefully acknowledge the University of Gadjah Mada, Yogyakarta, Indonesia, Research Directorate (Final Project Recognition, RTA: 3190/UN1/DITLIT/DIT-LIT/PT/2021) for funding, providing facilities, and publication support. Acknowledgment was also addressed to the head of Veterinary Disease Investigation Center, Subang, West Jawa, for his permission of laboratory work to perform the AI propagation and RT-qPCR detection. Special thank to technical support PT. Pimaimas Citra who sent the sample.

References

- Aamir, U.B., Wernery, U., Ilyushina, N., Webster, R.G., 2007. Characterization of avian H9N2 influenza viruses from United Arab Emirates 2000 to 2003. *Virology*. 361, 45-55. <https://doi.org/10.1016/j.virol.2006.10.037>
- Alexander, D.J., 2003. Newcastle and other avian paramyxovirus and pneumovirus infection. In: Saif YM, Barnes HJ, Fadly AM, Glisson JR, McDaugld LR, Swayne DE (Eds.). *Disease of Poultry, 11th edition*. Iowa State university, Ames, Blackwell Publishing Company. pp. 63-85.
- Bonfante, F., Mazzetto, E., Zanardello, C., Fortin, A., Gobbo, E., Maniero, S., Bigolaro, M., Davidson, I., Haddas, R., Cattoli, G., Terregino, C., 2018. A G1-lineage H9N2 virus with oviduct tropism causes chronic pathological changes in the infundibulum and a long lasting drop in egg production. *Vet. Res.* 49, 83. <https://doi.org/10.1186/s13567-018-0575-1>
- Burke, D.F., Smith, D.J., 2014. A recommended numbering scheme for influenza A HA subtypes. *PLoS ONE*. 9, e112302. <https://doi.org/10.1371/journal.pone.0112302>
- Capua, I., Marangon, S., 2000. The avian influenza epidemic in Italy, 1999-2000: a review. *Avian Pathology*. 29, 289-294. <https://doi.org/10.1080/03079450050118403>
- Cox, N.J., Kawaoka, Y., 1998. Orthomyxoviruses: influenza. In: Collier L, Balows A, Sussman M (Eds.). *Microbiology and Microbial Infection Vol. 1*. New York: L Virology, Oxford University Press, Inc. pp. 386-433.
- Dirjen PKH, Kementerian Pertanian, 2018. Deteksi Virus Avian Influenza dengan Teknik Real-Time Reverse Transcription Polymerase Chain Reaction (rRT-PCR). FAO SOP book, Balai Besar Veteriner Wates.
- El Houadfi, M., Fellahi, S., Nassik, S., Guerin, J.L., Ducatez, M.F., 2016. First outbreaks and phylogenetic analyzes of avian influenza H9N2 viruses isolated from poultry flocks in Morocco. *Virology Journal*. 13, 140. <https://doi.org/10.1186/s12985-016-0596-1>
- Horimoto, T., Kawaoka, Y., 2001. Pandemic threat posed by avian influenza A viruses. *Clin. Microbiol. Rev.* 14, 129-149. <https://doi.org/10.1128/CMR.14.1.129-149.2001>
- Jaleel, S., Younus, M., Idrees, A., Arsad, M., Khan, A.U., Ul-Haque, S.E., Zaheer, M.I., Tanweer, M., Towakal, F., Munibullah, Tipu M.Y., Sohail, M.L., Umar, S., 2017. Pathological Alterations in respiratory system during co-infection with low pathogenic avian influenza virus H9N2 and *Escherichia coli* in broiler chicken. *J. Vet. Res.* 61, 253-258. <https://doi.org/10.1515/jvetres-2017-0035>
- Javeen, T., Darnell, D., Gradi, E.A., Benali, Y., Kara, R., Guetarni, D., Rubrum, A., Seiler, P.J., Crumpton, J.C., Webby, R.J., Derrar, F., 2019. A H9N2 influenza viruses associated with chicken mortality in outbreaks in Algeria 2017. *Influenza. Other Respi Viruses*. 13, 622-626. <https://doi.org/10.1111/irv.12675>
- Jonas, M., Sahesti, A., Murwijati, T., Lestariningsih, C.L., Irine, I., Ayesda, C.S., Prihartini, W., Mahardika, G.N., 2018. Identification of avian influenza virus subtype H9N2 in chicken farms in Indonesia. *Prev. Vet. Med.* 1, 99-105. <https://doi.org/10.1016/j.prevetmed.2018.09.003>
- Kencana G.A.Y., Suartha I.N., Nurhandayani, A., Syamsidar, 2017. The characteristic of egg drop syndrome virus of medan isolate. *J. of Vet. Med and Animal Sci.* 1, 15-19.
- Kimura, M., 1980. A simple method for estimating evolutionary rate of base substitutions through comparative studies of nucleotide sequences. *J. Mol. Evol.* 16, 111-120. <https://doi.org/10.1007/BF01731581>
- Lai, V.D., Kim, J.W., Choi, Y.Y., Kim, J.J., So, H.H., Mo, J., 2021. First report of field cases of Y-280-like LPAI H9N2 strain in South Korean poultry farm: pathological findings and genetic characterization. *Avian Pathol.* 50, 327-338. <https://doi.org/10.1080/03079457.2021.1929833>
- Lee, Dong-hun., Song, C.S. 2013. H9N2 avian Influenza virus in Korea: evolution and vaccination. *Clin. Exp. Vaccine. Res.* 2, 26-33. <http://doi.org/10.7774/cevr.2013.2.1.26>
- Lee, Dong-hun., Fusaro, A., Song, C.S., Swayne, D.E., Suarez, D.L., 2015. Poultry vaccination directed evolution of H9N2 low pathogenicity avian influenza viruses in Korea. *Virology*. 488, 225-231. <https://doi.org/10.1016/j.virol.2015.11.023>
- Lestari., H. Wibawa, E.P., Lubis, R., Dharmawan, R.A., Rahayu, H., Mulyawan, K., Charoenkul, C., Nasamran, B., Poermadjaja, A., Amonsin, 2019. Co-circulation and characterization of HPAI-H5N1 and LPAI-H9N2 recovered from a duck farm, Yogyakarta, Indonesia. *Transbound. Emerg. Dis.* 67, 994-1007. <https://doi.org/10.1016/j.virol.2015.11.023>
- Maharani, N.R., Susetya, H., Wibowo, M.H., 2021. Characterization of hemagglutinin gene fragment of H9N2 avian influenza virus isolated from environmental live bird market in the greater Jakarta area. *Trop. Anim. Sci. J.* (Accepted, Unpublished Journal).
- Moosakhani, F., Shoshtari, A.H., Pourbakhsh, S.A., Keyvanfar, Ghorbani, H.A., 2010. Phylogenetic analysis of the hemagglutinin genes of 12 H9N2 influenza viruses isolated from chickens in Iran from 2003 to 2005. *Avian Dis.* 54, 870-874. <https://doi.org/10.1637/9103-101309-Reg.1>

- Muflihanah, Andesfha, E., Wibawa, H., Zenal, F.C., Hendrawati, F., Siswani, Wahyuni, Kartini, D., Rahayuningtyas, I., Hadi, S., Poeromadjaja, B., Mukartini, S., Tjatur Rasa, F.S., 2017. Kasus pertama low pathogenic avian influenza subtype H9N2 pada peternakan ayam petelur di Kabupaten Sidrap, Sulawesi Selatan, Indonesia. *Diagnosa Veteriner*. 16, 1-13.
- Nili, H., Asasi, K. 2002. Natural cases and an experimental study of H9N2 avian influenza in commercial broiler chicken of Iran. *Avian Pathology*. 31, 247-252. <https://doi.org/10.1080/03079450220136567>
- Nugroho, C.M.H., Silaen, O.S.M., Kurnia, R.S., Soejoedono, R.D., Poetri, O.N., Subandrio, A., 2021. Isolation and molecular characterization of the hemagglutinin gene of H9N2 avian influenza viruses from poultry in Java, Indonesia. *J. Adv. Vet. Anim. Res.* 8, 423-434. <https://doi.org/10.5455/javar.2021.h530>
- [OIE] World Organization for Animal Health, 2018. Avian Influenza (Infection with Avian Influenza Viruses), Chapter 3.3.4. OIE Terrestrial Manual 2018. pp. 821-843.
- Peacock, P.T., James J., Sealy, J.E., Iqbal, M., 2019. Review: a global perspective on H9N2 avian influenza virus. *Viruses*. 11, 620. <https://doi.org/10.3390/v11070620>
- Qi X., Tan, D., Wu, C., Tang, C., Li, T., Han, X., Wang, J., Liu, C., Li, R., Wang, J., 2016. Deterioration of eggshell quality in laying hens experimentally infected with H9N2 avian influenza virus. *Vet. Res.* 47, 35. <https://doi.org/10.1186/s13567-016-0322-4>
- Setiawaty, R., Soejoedono, R.D., Poetri, N.O., 2019. Genetic characterization of S1 gene of infectious bronchitis virus isolated from commercial poultry flock in West Java, Indonesia. *Vet. World*. 12, 231-235. <https://doi.org/10.14202/vetworld.2019.231-235>
- Shanmuganathan, L., Anggoro, D., Wibowo, M.H., 2017. Newcastle disease virus detection from organ sample using reverse transcriptase polymerase chain reaction. *JSV*. 35, 127-135. <https://doi.org/10.22146/jsv.29300>
- Teng, Q., Xu, D., Shen, W., Liu, Q., Rong, G., Li, X., Li, Z., 2016. A single mutation at position 190 in hemagglutinin enhances binding affinity for human type sialic acid receptor and replication of H9N2 avian influenza virus in mice. *J. Virol.* 90, 9806-9825. <https://doi.org/10.1128/JVI.01141-16>
- Tong, S., Zhu, X., Li, Y., Shi, M., Zhang, J., Bourgeois, M., Yang, H., Chen, X., Recuento, S., Gomez, J., Chen, L.M., Johnson, A., Tao, Y., Dreyfus, C., Yu, W., McBride, R., Carney, P.J., Gilbert, A.T., Chang, J., Guo, Z., Davis, C.T., Poulson, J.F., Steven, J., Rupprecht, C.E., Holmes, E.C., Wilson, I.A., Donis, R.O., 2013. New world bats harbor diverse influenza A viruses. *Plos Pathog.* 9, e1003657. <https://doi.org/10.1371/journal.ppat.1003657>
- Triosanti, L.S., Wibowo, M.H., Widayanti, R., 2018. Molecular characterization of hemagglutinin-neuraminidase fragment gene of Newcastle disease virus isolated from periodically-vaccinated farms. *Vet. World*. 11, 657-666. <https://doi.org/10.14202/vetworld.2018.657-666>
- Wibowo, M.H., Ginting, T.E., Asmara, W., 2019. Molecular characterization of pathogenic 4/91-like and QX-like infectious bronchitis virus infecting commercial poultry farms in Indonesia. *Vet. World*. 2, 277. <https://doi.org/10.14202/vetworld.2019.277-287>
- [WHO] World Health Organization, 2002. WHO manual on animal influenza. Diagnosis and surveillance. Available at: <http://www.who.int/>. [Date accessed: 12 September 2020]