

Combined therapy of laser puncture and surgical repositioning of rectal prolapse accompanied by rupture in goats

Rr Soesatyoratih*

Division of Surgery and Radiology, School of Veterinary Medicine and Biomedical Sciences, IPB University, Bogor

ABSTRACT: Rectal prolapse occurs when the rectum protrudes from the anus. This article reports a case of a male goat named Jimmy, presented to the Cimanggu Animal Clinic with a mass protruding from his anus. Physical examination revealed diarrhea, and the mass was a rectal prolapse with three ruptures in the rectal wall accompanied by swelling and bleeding. Jimmy was diagnosed with rectal prolapse with ruptures. Treatment involved suturing the ruptures and performing laser puncture at the suture sites and prolapsed rectum at the Lian Hua point, followed by repositioning. Additional laser puncture was performed after repositioning at the GV-1, GV-20, ST-36, and Gang Tuo acupuncture points using 0.5 Joules of energy and 50 mW of power. Metronidazole was administered intravenously at 75 mg/kg body weight for 3 days to manage the diarrhea. Improvement was noted on the third day post-surgery, with the goat's feces forming pellets and the anal sphincter condition improved. One month after surgery, the goat was discharged with pellet-shaped feces, good appetite, strong anal and sphincter condition, and no recurrence of prolapse. This case highlights the successful management of rectal prolapse in goats by using a combination of surgical intervention, laser puncture, and antibiotic therapy.

Keywords:

rectal prolapse, rectal rupture, reposition, laser puncture

■ INTRODUCTION

Rectal prolapse is a condition in which the rectal tissue protrudes from the anus, exposing the mucosa. It can occur due to high intrapelvic pressure and abdominal tension, and is often caused by chronic diarrhea, coughing, or coccidiosis (Arulkumar *et al.* 2022). If left untreated, rectal prolapse in sheep or goats can be fatal. In the case of Jimmy, prolapse was categorized as complete, with the entire rectal layer protruding from the anus (Chakrabakti 2004). Once rectal prolapse occurs, venous and lymphatic return is disrupted, leading to rapid swelling and edema. This exacerbates the straining response and worsens the prolapse. Immediate evaluation and prompt treatment are crucial for minimizing damage from external trauma and continued tenesmus (Hartnack & Jones 2017).

The main purpose of acupuncture is to restore the normal transmission of nerve impulses and provide an energy balance (Dharmojo 2013). According to Stux (2001), acupuncture can influence blood pressure, gastrointestinal motility, autonomic nervous system activity, and release of hormones and blood chemicals. This case study reports the treatment of a goat with rectal prolapse accompanied by rupture using a combination of surgical repositioning therapy, laser puncture, and antibiotic drug therapy.

■ CASES

Signalment: Jimmy, a male goat, is black and white, weighs 12 kg, and is four months old. **Anamnesis:** a mass protruding from the goat anus. **Physical Examination:** Jimmy revealed diarrhea and rectal prolapse accompanied by three ruptures in the rectal wall, edema, and bleeding (Figure 1A). **Diagnosis:** Rectal prolapse. **Therapy:** The treatment involved Rectal repositioning surgery combined with acupuncture therapy using laser puncture and antibiotic administration. **Acupuncture Points and Antibiotics:** Acupuncture points used were Lian Hua, GV-1, GV-20, ST-36, and Gang Tuo (Xie & Priest, 2007), with an energy of 0.5 Joules and a power of 50 mW. Metronidazole antibiotics were administered intravenously at 75 mg/kg BW once daily to manage diarrhea (Allen *et al.*, 1993). **Rectal Reposition Surgery Management:** The surgical area was shaved and cleaned using soap, 70% alcohol, and betadine. Regional cranial epidural anesthesia was administered between lumbar seven and sacrum 1 using 2% lidocaine injection at a dose of 7 mg/kg BW (Venkatachalam *et al.*, 2018). The prolapsed area was cleaned with 0.9% NaCl, and the ruptured rectum was sutured using a PGA 3/0 round needle thread using a double continuous suturing technique. Laser puncture and

Received: 24-02-2024 | Revised: 20-03-2024 | Accepted: 23-03-2024

© 2024 CC-BY-SA. This is an Open Access article distributed under the terms of the Creative Commons Attribution ShareAlike 4.0 International License (<https://creativecommons.org/licenses/by-sa/4.0/>).

Lian Hua acupuncture point were applied at the suture site (Figure 1B). The prolapse was then repositioned, and a tobacco pouch suture was performed on the subcutaneous anus. Laser puncture was subsequently performed at the GV-1, GV-20, ST-36, and Gang Tuo acupuncture points. Postoperative Acupuncture and Antibiotic **Therapy:** Acupuncture therapy using laser puncture was conducted three times a week at the GV-1, GV-20, ST-36, and Gang Tuo points over five sessions. Metronidazole antibiotics were administered once daily for five days.

■ RESULT AND DISCUSSION

Laser puncture technology involves using a laser directed at acupuncture points that act as biological receptors connected to specific organs, thereby enhancing their capacity and efficiency (Adikara 2019). The torn rectum was sutured using a PGA 3/0 absorbable suture thread with a round needle using the double continuous technique. According to Hartnack and Jones (2017), intestinal suturing is typically performed using simple continuous and Cushing sutures. However, owing to the edematous condition of the rectum, a double continuous suture technique was employed instead.

Xie & Preast (2007) recommend specific acupuncture points for rectal prolapse cases, including Lian Hua (multi-puncture on the prolapsed rectal mucosa), Gang Tuo (A-Shi point located 1 cun lateral to the anus bilaterally), Bai Hui (GV-20), Hou San Li (ST-36) for gastrointestinal and diarrhea treatment, and Hou-hai (GV-1) as the Luo connecting point on the GV channel for diarrhea.

During the first therapy session, the stool remained liquid, and the anus was still swollen. In the second session, the stool began to soften and swelling decreased. In the third session, the stool had formed granules, and the anal sphincter started to strengthen. The therapy was continued until the fifth session. After one month of postoperative care, the goat's condition significantly improved, and rectal prolapse did not recur.

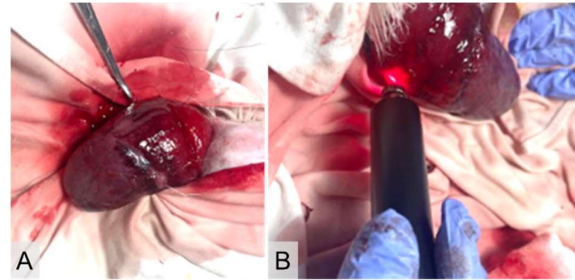


Figure 1. Condition of goats with prolapse and therapy. (A) Pro-lapsus rectum of Jimmy goat accompanied by rupture, and (B) Laser puncture at Lian Hua acupuncture point.

■ CONCLUSION

Rectal prolapse repositioning surgery, combined with laser puncture therapy and metronidazole antibiotics, effectively treated rectal prolapse in Jimmy goats. Significant healing was observed after the third laser puncture session, with continued improvement over the five sessions. After one month of treatment, there was no recurrence of the rectal prolapse.

■ AUTHOR INFORMATION

Corresponding Author

*RS: susatyoratih@yahoo.co.id

Division of Surgery and Radiology, School of Veterinary Medicine and Biomedical Sciences, IPB University, Jln. Agatis Kampus IPB Dramaga, Bogor, 16680, INDONESIA.

■ REFERENCES

- Adikara RTS. 2019. *Laserpunktur Hewan*. Surabaya: Airlangga University Press hlm 45.
- Allen DG, Smith DA, Pringle JK. 1998. *Handbooks of Veterinary Drugs*. US: J. B. Lippincott Company. 886 pp.
- Arulkumar S, Arunkumar R, Ragulraj S, Priyadharsini R. 2022. Correction and management of rectal prolapse in indigenous goat: A case report. *The Pharma Innovation Journal*. SP-11 (8):698-699.
- Chakrabarti A. 2018. *Text Book of Clinical Veterinary Medicine*. 4th ed. India, New Delhi: Kalyani Publishers,
- Dharmojono. 2013. *Basics of Acupuncture and Veterinary Moxibustion-Small Animals*. Jakarta (ID): Trubus Agriwidya. 151 pp.
- Hartnack A, Jones M. 2017. *Surgery of the sheep and goat digestive system*. Farm Animal Surgery. 2nd ed US: Elsevier Publishing. 561-567.
- Stux G, Hammerschlag R. 2001. *Clinical Acupuncture, Scientific Basis*. Berlin (DE): Springer. p 1-28.
- Venkatachalam D, Chambers P, Kongara K, Singh P. 2018. Toxicity and pharmacokinetic studies of lidocaine and its active metabolite, monoethylglycinexylidide, in goat kids. *Animals (Basels)*. 8(8):142.
- Xie H, Preast V. 2007. *Xie's Veterinary Acupuncture*. US: Blackwell Publishing. 320.